

Three-Dimensional (3D) Reconstruction for Detecting Shape and Volume of Lung Cancer Nodules

Rodiah¹, Sarifuddin Madenda², and Fitrianiingsih¹

Abstract—The development of CT scanning technology as a digital image recorder has provided facilities for oncologists in analyzing the presence of cancer in patient's organs. Visually, oncologists analyze it by looking at the CT slices to ascertain whether any cancer nodules in the lung are present. The center line of nodules is used to calculate the volume of nodules for all slices. Volume is used to monitor the rate of cancer growth. Another way is the shape of cancer nodules. However, since the CT scan images are in the form of two-dimensional (2D), it is hard for oncologists to see the full three-dimensional (3D) shape of the cancer nodules. Based on that matter, this study aimed to develop algorithm that can automatically detect and calculate volume of nodules for all slices in 3D reconstruction. 3D reconstruction of cancer nodules is performed through linear interpolation approach. The results of the developed algorithm, tested through a number of slice images from lung CT scan, showed that the approach and algorithm are able to reconstruct nodule shape in 3D and calculate volume automatically. The results obtained are expected to be able to help oncologists provide accurate information of cancer nodules as well as volume and shape of the cancer nodules in 3D surface.

Keywords— Cancer nodules, Interpolation, Lung, Volume, 3D Reconstruction.

I. INTRODUCTION

The World Health Organization (WHO) and Union for International Cancer Control have predicted that there will be an increase of people with cancer by 300% worldwide in 2030. 70% of the increase will take place in developing countries such as Indonesia (source: <http://www.uicc.org/>, 2013). One type of cancer which causes the most deaths compared to other types is lung cancer. Increase in the number of people with lung cancer is predicted to double, from 65.000 in 2010 into 137.000 in 2040 (<http://www.bbc.co.uk/>, 2013). However, advanced research which produce state-of-the-art therapy for cancer enable to minimize the spread of cancer in various ways. One of them is through early detection. Early detection on lung cancer can be applied through screening program. The most commonly used screening program to detect lung cancer is imaging technique by using CT (Computed Tomography) scan. CT scan is imaging technology that can perform acquisition of lung image and provide description of objects appeared in lung.

In addition to general and physical symptoms of lung cancer (e.g. hemoptysis), appearance of nodules in lung, as visible from CT scan image, is considered as one of the indications in diagnosing lung cancer. Basic principle of CT scan is similar to any known radiography devices. Both devices equally utilize intensity of canal radiation after passing an object to take an image. Information of image displayed by CT scan does not overlap because CT scan is able to take image which can be observed not only on ray in perpendicular position (as in roentgen ray photo). CT scan image is able to provide information on inspected cross section object, among others is information of nodules in lung.

Nodules in lung are small round or oval-shaped growth in the lung, usually not more than 3 to 4 cm in diameter (not more than 6 cm). Lung nodules can be identified as cancer which may be caused by other serious diseases (Djojodibroto, 2007). Nodules in the lung are often attached to blood vessels, thus the grey level of the nodules is very similar to other parts in the lung.

Process of detecting nodules is one of the difficult stages in diagnosing lung cancer. It is because there are many other objects than nodules in the lung (e.g. blood vessels, hilum, mediastinum). To simplify process of detecting nodules in the lung, an algorithm is needed to distinguish nodules from other objects in the lung in order to perform process of extraction.

Research to detect lung cancer nodules was conducted through surface reconstruction on input image within the CT scan image of lung (Koszmider and Strzecha, 2006). The reconstruction was conducted through preliminary processing which included morphological operations of dilation, erosion and thinning. Reconstruction was conducted by tracing neighboring dots through outline tracing which then stored as information in array to reconstruct image into 3D. For non-neighboring dot, it could not be stored and tracing procedure ended in temporary array at dot which had one neighbor. Many iterations on pixels which were selected as reconstructed nodule criteria, resulted in error in distinguishing removable and non-removable pixels. This study proposes algorithm to reconstruct every slice of extracted 2D nodule area into 3D nodule object. The results can provide information regarding shape and volume of nodules as depicted in the lung image. Hence it will assist oncologists in providing appropriate treatments for patients with lung cancer.

II. DESCRIPTION OF WORK

A. Input Image

Input image used in this study is post-contrast image with resolution of 512 x 512 pixels and 630 x 630 pixels; with slice thickness/increment 3.0mm and 8.0mm; with DICOM (.dcm) format. Images used for reconstruction

¹Rodiah and Fitrianiingsih are with Departement of Informatics, Universitas Gunadarma, Depok, Indonesia. E-mail: rodiah@staff.gunadarma.ac.id; fitrianiingsih@staff.gunadarma.ac.id.

²Sarifuddin Madenda is with Department of Informatics, STMIK Jakarta STI&K, Jakarta, Indonesia. E-mail: sarif_madenda@yahoo.com.

process were extracted images containing detected nodules (Rodiah and Sarifuddin Madenda, 2013). Nodule extraction process was conducted through geometric shape approach and intensity as can be seen in Figure 2.

Extraction of nodule area in the lung image was based on measurement by using geometric approach on object, which consists of: Area Value, Bounding Box which is the smallest rectangle containing region Q as number of image dimensions with angle and width parameters in the lung image and ratio in which nodules were represented as objects in the shape of circle, with symmetrical shape of which area and perimeter of the circle can be identified. Area and perimeter value, as properties of this circle, can be measured on regions of extracted nodule images as basic measurement of the spherical shape. Objects in lung image which have spherical shape will have ratio of 1, in which the length of the major axis is proportional to the length of minor axis. Detected objects with ratio close to 1 and have same intensity or close to nodule intensity will be extracted or retained. For objects which do not have the same characteristics as nodules will be deleted (Rodiah dan Sarifuddin madenda, 2013).

B. Nodule Reconstruction Algorithm

Reconstruction on extracted images was conducted to observe nodules in 3D and automatically detect volume of the nodules on lung image. In general, outline of 3D reconstruction can be seen in figure 3.

The followings are algorithm used for reconstructing extracted images containing nodules from a number of CT scan image slices of the lung:

1. Conducted sampling on pixel dots (x,y) of extracted images in figure 3.16. The sampling process was conducted for having spatial coordinate digitizing process (x,y) .
2. Stored the sampling dots in a matrix that has data record structure and used them as control dots in interpolation process. Linear interpolation process on the sampling dots was conducted by:
 - a. Determining 2 points P1 and P2 with coordinate (x_1,y_1) and (x_2,y_2) respectively
 - b. Determining point x from point which will be plotted
 - c. Calculating value y with linear interpolation equation:

$$y = \frac{y - y_1}{x_2 - x_1} (x - x_1) + y_1 \quad (1)$$
 - d. Displaying the new point value of $Q(x, y)$
3. Searched for connections between dots from the established image in the form of dots compilation.
4. Of the established reconstructed image, then nodule volume could be automatically detected based on the total amount of area from each image slice multiply by $Z_{thickness}$ as thickness of CT scan image slice of the lung. $Z_{thickness}$ has various thickness values namely 2-8 mm. The nodule volume is formulated as follows:

$$V = \sum \text{Nodule Area per slice} * Z_{thickness} \quad (2)$$

5. Of the successfully reconstructed nodule images along with information of nodule volume, rotation could also be conducted to identify surface shape of the nodule. Shape of the nodule surface was also

used as one of the predictors of malignancy in cancer. Rotation on 3D nodule images was conducted by using coordinate axis as central of three rotations namely rotation of axis x, rotation of axis y and rotation of axis z as in figure 4.

III. RESULT AND DISCUSSION

A. How Oncologists Determine Area and Volume of Nodules

The current CT scan technology used by a number of hospitals in Indonesia, including RSCM (Cipto Mangunkusumo Hospital), is quite sophisticated, but calculation of area and volume of nodules is still conducted semi-automatically. Of hundreds of image slices generated by CT scan, oncologists must see them with plain eyes one by one and decide which slice contains the biggest nodule, for example slice as outlined in figure 5. By seeing the image slice, as outlined in figure 5, oncologists then draw the longest diameter line of the nodule manually. The diameter and slice will then be used as reference for CT scan software to calculate nodule area on each slice and nodule volume of all slices containing nodules. These processes are semi-automatic and take time to determine the volume of nodules.

If the lung image slice in figure 5 is taken as reference then blue line of the nodule means plotted line drawn by oncologists and automatically will indicate the longest diameter value of the spherical nodule. Based on this value, the nodule area is then calculated as follows:

1. diameter $d = 40,44$ mm, radius $= r = d/2 = 20,22$
2. Area $= \pi r^2 = 3,14 \times (20,22 \text{ mm})^2 = 1283,784 \text{ mm}^2$

This semi-automated measurement may lead to miscalculation of area and volume. In fact, the above nodule area of each CT scan image slice and nodule volume of all slices are actually smaller than calculation in figure 5. This inevitably may cause misleading information. This miscalculation is apparent when compared with calculation using a number of pixels to detect nodule area which is extracted automatically.

Table 1 displays examples of different area calculations as benchmarking between semi-automated calculation and automated calculation on some image slices.

B. Analysis of Comparing Calculation of Area and Volume

The followings are comparisons of how oncologist calculated (Abdullah, 2009) based on area value automatically on each CT scan slice.

- a. Measurement conducted by oncologist was using different nodule volume of tumour from Armstrong (Armstrong, 2005) who used measurement based on the largest diameter on one side alone.
- b. The nodule volume of tumour was calculated manually on each lung image slice in accordance to the nodule shape of that slice. If the shape is like a tube, then the formula to calculate the volume is $2\pi/7 r^2 \times \text{height}$ (r =radius). If the shape is like a cube, then the formula to calculate the volume is $\text{side} \times \text{side} \times \text{side}$. If the shape is like prism, then the formula to calculate the volume is $1/3$ of basic area \times height (Abdullah, 2009).

c. Diagnosis results and comparisons of volume calculation as calculated by oncologist are displayed as follows:

$$V = \sum_{i=1}^n V_i$$

$$V = V_1 + V_2 + V_3 + \dots + V_{22}$$

$$V_i = L_i \times t$$

$$V_i = \pi r^2 \times t$$

$$V = 360,405 + 1111,11 + 1547,235 + 2130,792 + 2587,29 + 2850,09 + 3106,2 + 3323,34 + 3602,94 + 3851,352 + 3950,1 + 4005,6 + 3961,35 + 3931,5 + 3964,35 + 3644,28 + 2877,795 + 2125,29 + 1395,3 + 1020,3 + 679,5 + 274,29$$

$$V = 56300,41 \text{ mm}^3$$

$$V = 56,30041 \text{ cm}^3$$

In which:

V = Nodule total volume (in cm^3)

L^i = Area per nodule (in mm^2)

i = slice

t = slice thickness (for this image, the thickness is 3.0 mm)

Volume calculation for the case of tumour in left lung from table 2 by using semi-automated calculation, the result is $56,300 \text{ cm}^3$, while using automated calculation, the result is $53,631 \text{ cm}^3$. It means there is a gap around 4%. On another image with nodule attaching to hilum, the volume calculation using semi-automated calculation is 106 cm^3 , while using automated calculation, the volume is $100,396 \text{ cm}^3$. It is possible that in this case, calculation of volume using semi-automated calculation is 5% more than using automated calculation because the nodule shape of the image is irregular hence the volume is calculated by taking radius of the biggest nodule on a number of image slices. Automatically, calculating volume using semi-automated calculation will provide bigger result. Figure 6 provides an example of volume calculation using semi-automated calculation (RSCM, 2011). The measurement was conducted by drawing a line to obtain its diameter. On image a and b, with respective direction of axial and sagittal, it can be seen that drawing line to obtain nodule diameter does not represent the whole nodule in the lung image.

C. Results of 3D Nodule Reconstruction

To reconstruct nodules in 3D, Zthickness information and all image slices containing nodules from previous results of extraction were used. Zthickness is distance of taking CT scan image or distance between two slices recorded by CT scan. The distance is usually varied from 2 to 8 mm per slice. For example, results of

reconstruction in this study used two examples as elaborated previously, in which value of Zthickness can be read automatically in CT scan image file. Results of reconstruction for cancer nodules on case of image slices in table 2 are displayed in figure 7.

IV. CONCLUSION AND SUGGESTION

Based on the test results, the developed method and algorithm are successful in automatically detecting and reconstructing cancer nodules from extracted images on every slice of lung CT scan images. Reconstructed algorithm from 2D object slice into 3D object through linear interpolation approach is successful in reconstructing lung cancer nodules into 3D image. This 3D image can be rotated that enables oncologists to see surface and shape of the cancer from many angles. Hence, the 3D image can help oncologists in giving further medical treatment. Cancer volume can also be calculated automatically.

Although the test images used have various slice thicknesses, the developed algorithm is successful in detecting and calculating nodule volume in lung automatically. However, further test should be conducted on other CT scans with various cases of nodules especially on lung cancer cases of which nodules are difficult to be detected through image device. It is suggested to have further research by involving expert judgment (radiology specialist) especially in interpreting and diagnosing lung cancer from a lung CT scan image.

REFERENCES

- [1]. Djojodibroto Darmanto, "Respirologi (Respiratory Medicine)", Buku Kedokteran EGC, Cetakan I, ISBN 978-979-448-980-2, 2007
- [2]. Disha Sharma, Gagandeep Jindal, "Identifying Lung Cancer Using Image Processing Techniques", International Conference on Computational Techniques and Artificial Intelligence (ICCTAD), 2011
- [3]. Gonzalez, Rafael .C, Woods Richard E, Eddins Steven L, 2009, Digital Image Processing, Prentice-Hall
- [4]. Koszmider Tomasz, Strzecha Krzysztof, 2006, 3D Lungs Surface Reconstruction From Computed Tomography Images, Computer Engineering Department At Technical University Of Lodz, Poland, Imeko World Congress Metrology For A Sustainable Development September, 17 – 22, Rio De Janeiro, Brazil
- [5]. Rodiah dan Sarifuddin Madenda, 2013, Ekstraksi Dan Perhitungan Luas Nodul Citra CT-Scan Kanker Paru, Konferensi Nasional Sistem Informasi (KNSI), ISBN 978-602-17488-0-0, Bumigora, Mataram-Nusa Tenggara Barat, 2013
- [6]. Rumah Sakit Cipto Mangunkusumo (RSCM), 2011, Departemen Radiologi Fakultas Kedokteran Universitas Indonesia (FKUI)
- [7]. URL : <http://www.uicc.org/>, 2013, tanggal akses : 12 Mei 2013
- [8]. URL : <http://www.bbc.co.uk/>, 2013, tanggal akses : 13 Mei 2013.

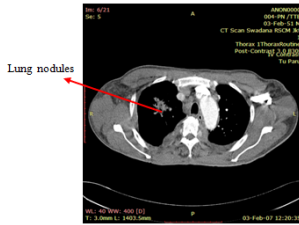


Figure 1. CT scan of Abnormal Lung (source: RSCM, 2011)

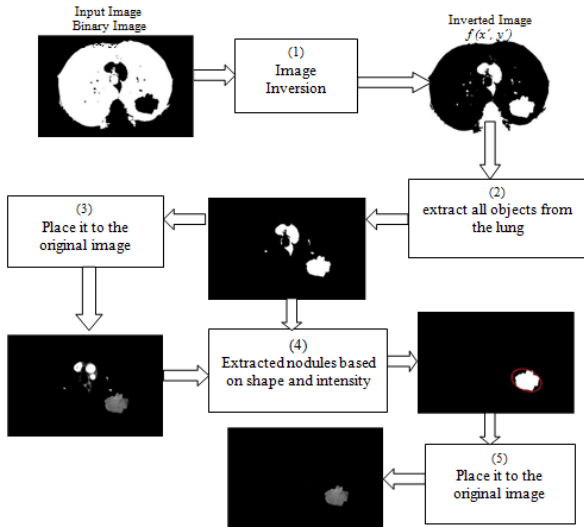


Figure 2. Outline of Nodule Extraction Process based on Shape and Intensity (Rodiah and Sarifuddin madenda, 2013)

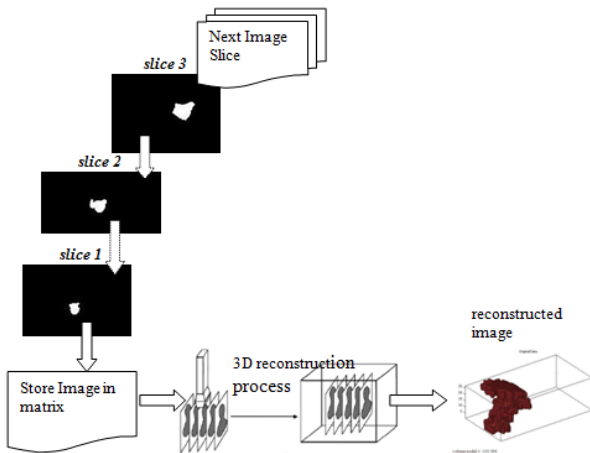


Figure 3. General outline of 3D Reconstruction process of Nodules

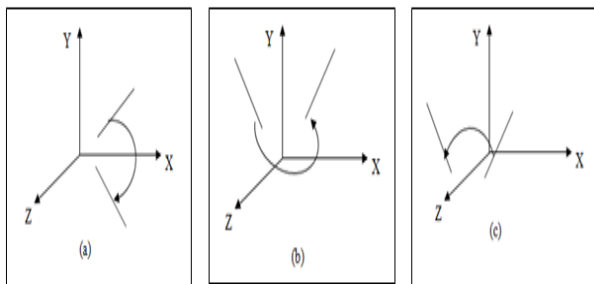


Figure 4. 3D Object Rotation (a). Rotation of Axis x (b). Rotation of Axis y (c). Rotation of Axis z

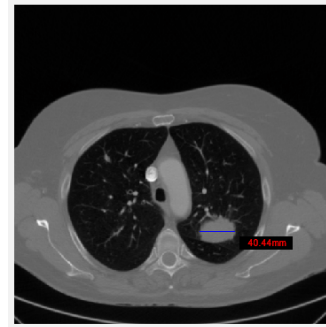


Figure 5. Lung Image Nodule with Diameter

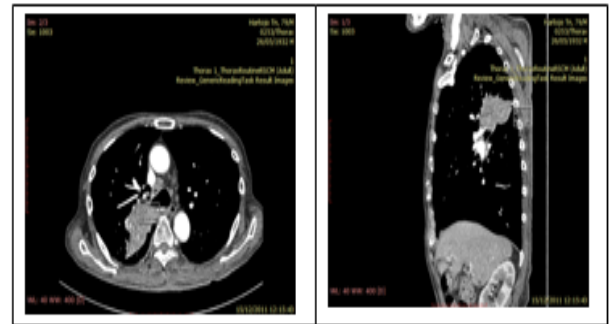


Figure 6. Example of volume calculation semi-automatically (RSCM, 2011)
(a). CT scan Axial direction. (b). CT scan Sagittal direction

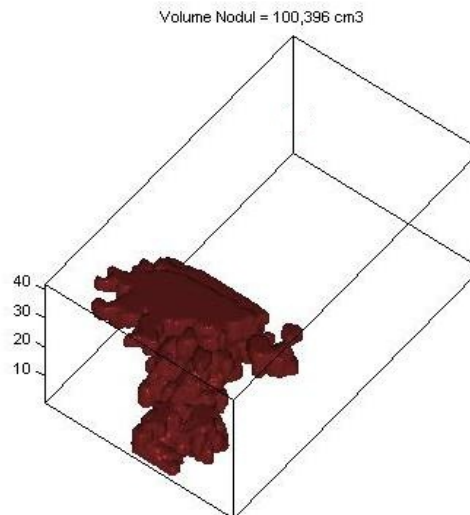



Figure 7. Results of 3D Nodule Reconstruction

TABLE 1.
RESULTS OF EXTRACTED NODULE AREA WITH OBJECT GEOMETRY
SHAPE APPROACH AND AREA CALCULATION









Slice	CT Scan Image	Extraction Image	wide semi-automatic nodules (mm ²)	Wide automatic nodules (mm ²)
1			120,135	111,183
2			370,370	348,206
3			515,745	482,131
4			710,264	665,584

TABLE 2.
SUMMARY OF NODULE AREA CALCULATION AS DETECTED ON EACH
SLICE WHICH THEN USED TO CALCULATE NODULE VOLUME

Slice (i)	Wide Semi-Automatic Nodules (mm ²) (Li)	Wide Automatic Nodules (mm ²) (Li)
1	120,135	111,183
2	370,370	348,206
3	515,745	482,131
4	710,264	665,584
5	862,430	806,585
6	950,030	929,897
7	1,035,400	997,112
8	1,107,780	1,054,200
9	1,200,980	1,133,100
10	1,283,784	1,198,300
11	1,316,700	1,234,400
12	1,335,200	1,279,600
13	1,320,450	1,275,600
14	1,310,500	1,267,000
15	1,321,450	1,274,600
16	1,214,760	1,191,700
17	959,265	915,746
18	708,430	661,540
19	465,100	432,099
20	340,100	310,303
21	226,500	203,667
22	91,430	84,399
Σ wide nodules/slice	18,766,800	17,876,950